



## OOCYTE DEVELOPMENT IN THE FRESH WATER SPOTTED SNAKEHAD, *CHANNA PUNCTATA* (BLOCH, 1793)

**KULSANGE B.K. AND MASRAM S.C.**

PGTD of Zoology, RTM Nagpur University, Nagpur-440033, India

suresh.masram@gmail.com

### Abstract:

Teleosts possess well defined breeding or reproductive cycle. On the basis of shape, size, colour of the ovary different phases viz., preparatory phase, early maturing phase, prespawning phase, spawning phase and spent phase are recognized in teleosts. From the end of preparatory phase to spawning phase developing oocytes pass through different stages. During this journey vitellogenesis and maturation is an important event for oocyte development. Various stages of female gametes of *Channa punctata* were analyzed. Mature *Channa punctata* were collected by lakes in and around Nagpur city. Different phases of ovarian maturation were confirmed by calculating gonadosomatic index (GSI). Ovarian tissues were fixed in Bouin's fixative, dehydrated in graded alcohol, cleared in xylene, embedded in paraffin wax and thus blocks were prepared. Blocks were cut in 6-7 µm thick sections. Sections were stained with Haematoxyline and Eosin (HE). Oocyte morphology, nucleus-cytoplasm (N/C) ratio range were studied. Morphometric analysis of different oocytes was carried out with help of Tcapture version 4.3.0.602 software.

**Keywords:** *Channa punctata*, oocytes.

### Introduction:

A pair of folded sac like outgrowth of pharyngeal outgrowth provide all the species of the *Channa* viz., *C. punctata*, *C. marulius*, *C. striata* and *C. gachua* a tenacity to survive outside the water for considerable period (Chakrabarty, 2006). Oogenesis of teleosts has been thoroughly studied. The various stages of oocytes is based on peculiar morphological, histological, physiological and / or biochemical cell characteristics (i.e. oocyte size, shape, quantity and distribution of different cytoplasmic as well as nuclear inclusions (Casadevall et al., 1993; Tyler and Sumpter, 1996). Histological studies of gonad of species reveal gonadal development (West, 1992). Ovarian cycle and spawning season of *Ophiocephalus punctatus* inhabiting Jammu water was documented (Malhotra et al., 1978) where six stages of oocytes were reported by following method of Srivastava and Rathi (1970). Variation in gonadal cycle, spawning time and spatial behaviour of this fish were well documented (Swaroop, 1954; Belsare, 1962; Malhotra et al., 1978).

### Materials and methods

Matured female *C. punctata* of 150-200 gm weight were collected / procured from various water bodies of eastern Vidharbha. Fishes were acclimatized in aquaria for one week. After sacrificing fishes, ovaries were dissected out and fixed in Bouin's fluid. After fixation, ovaries were cutted in pieces and cutted tissues were washed and transferred to 70% alcohol and dehydrated in graded alcohol, cleared in xylene and embedded in paraffin wax at 60°C- 62°C. Blocks of tissues were

trimmed and serial sections of these blocks were cut on Cambridge (rocking) microtome at 6-8 µm thickness in transverse plane. The sections were fixed on clean slide and later stained by Haematoxyline- Eosine procedure (Lillie, 1965). Sections were observed in Karl Zeiss microscope and photographed by Tucsen USB 2.0 H series camera. Morphometric analysis of different oocytes was carried out with help of Tcapture version 4.3.0.602 software.

Gonado-somatic index was calculated by formula:

$$GSI = (W_g \times W^{-1}) \times 100$$

Where:  $W_g$ -Weight of gonads (g).  $W$ - Body weight (g).

Results were expressed as the mean and standard error of mean (SEM). Difference between means were analysed by one-way ANOVA. Level of significance was set at  $P \leq 0.05$ .

### Observation:

Based on GSI, morphology of ovaries and presence of oocyte present identified five phases of reproductive cycle viz., Preparatory phase (Mid December- February), Early maturing phase (March- April), Prespawning phase (May), Spawning phase (June – October) and Spent phase (November- Mid December). GSI of preparatory phase was lowest (0.58±1.2) (Table 1, Graph 1). GSI was slightly higher in early maturing phase (1.99±0.9) (Table 1, Graph 1). GSI was further significantly rises in prespawning phase (4.49±0.89) ( $p < 0.05$ ) (Table 1, Graph 1). GSI was maximum in spawning phase and significantly higher than prespawning phase ( $p < 0.05$ ) (14.41± 0.73) (Table 1, Graph 1). In spent phase GSI was lowered significantly to 0.60 ±1.03. No significant

difference observed between GSI of preparatory and spent phase ( $p < 0.05$ ).

Oogenesis initiated with development and growth of oocytes (Gomes et al., 2001). Overall six oocyte development stages were identified for *C. punctata*.

Primary oogonia: With  $16.52 \pm 1.4 \mu\text{m}$  these were smallest oval cells (Fig. 1a) (Table 2, Graph 2). Primary oogonias either present singly or they present in cluster. Cytoplasm is strongly basophilic.

Chromatin nucleolus oocytes: These oocytes develop from primary oogonias therefore they were observed in proximity of primary oogonias. They were slightly larger ( $36.47 \pm 1.7 \mu\text{m}$ ) (Table 2, Graph 2). They had a large and lightly stained nucleus. A single nucleolus located toward nuclear membrane (Fig. 1b).

Early perinucleolar oocyte: Further growth ( $47.62 \pm 0.87 \mu\text{m}$ ) was observed in early perinucleolar oocyte (Fig. 1c) (Table 2, Graph 2). It had slightly less basophilic cytoplasm. Larger, regular rounded nucleus with several small nucleoli were seen towards peripheral margin of nucleoplasm (Fig. 1c).

Late perinucleolar oocyte: Significant growth observed in late perinucleolar oocyte ( $64.45 \pm 0.87$ ) (Fig. 1d) (Table 2, Graph 2). In late perinucleolar oocyte, nucleus become irregular and multiple cortical alveoli appears towards periphery of cytoplasm (Fig. 1d).

Vitellogenic oocyte: Vitellogenic oocyte is larger than early oocytes stages ( $130.46 \pm 1.12$ )

(Table 2, Graph 2). Shrinkage in nucleoplasm observed in vitellogenic oocyte (Fig. 1e). Cytoplasm of vitellogenic oocyte was filled with cortical vesicles (Fig. 1e).

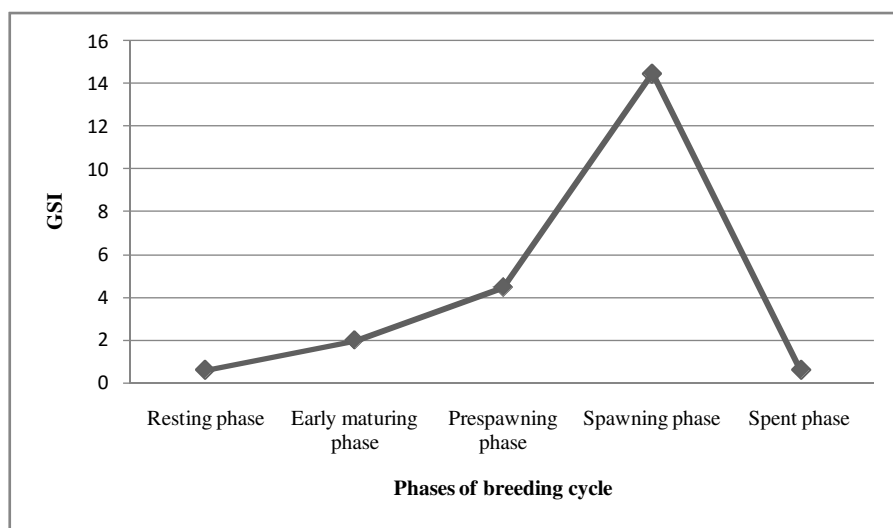
Ripe oocyte: They were largest oocytes ( $284.99 \pm 0.92$ ) (Table 2, Graph 2). Cytoplasm of ripe oocyte was completely filled cortical vesicles as well as yolk granules. Disintegration of nucleus is complete in ripe oocyte. The cytoplasm of ripe oocyte was more voluminous and had a grainy appearance.

**Table 1:** GSI in various phases of breeding cycle.

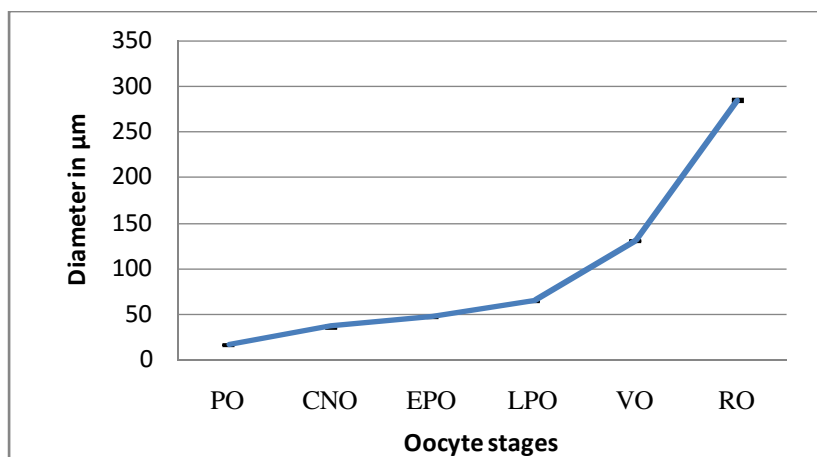
Phases	GSI
Preparatory phase	$0.58 \pm 1.2$
Early maturing phase	$1.99 \pm 0.9$
Prespawning phase	$4.49 \pm 0.89$
Spawning phase	$14.49 \pm 0.73$
Spent phase	$0.60 \pm 1.03$

**Table 2:** Morphometric analysis of oocytes stages in *C. punctata*

Oocyte stage	Diameter in $\mu\text{m}$
Primary oogonia	$16.52 \pm 1.4$
Chromatin nucleolus oocyte	$36.47 \pm 1.7$
Early perinucleolar oocyte	$47.62 \pm 0.87$
Late perinucleolar oocyte	$64.45 \pm 0.76$
Vitellogenic oocyte	$130.46 \pm 1.12$
Ripe oocyte	$284.99 \pm 0.92$



**Graph 1:** Oscillation in GSI during various phases of breeding cycle



**Graph 2: Diameter (μm) of oocytes in C. punctata**(PO- Primary oogonia, CNO-Chromatin nucleolus oocyte, EPO-Early perinucleolar oocyte, LPO-Late perinucleolar oocyte, VO-Vitellogenic oocyte, RO-Ripe oocyte)

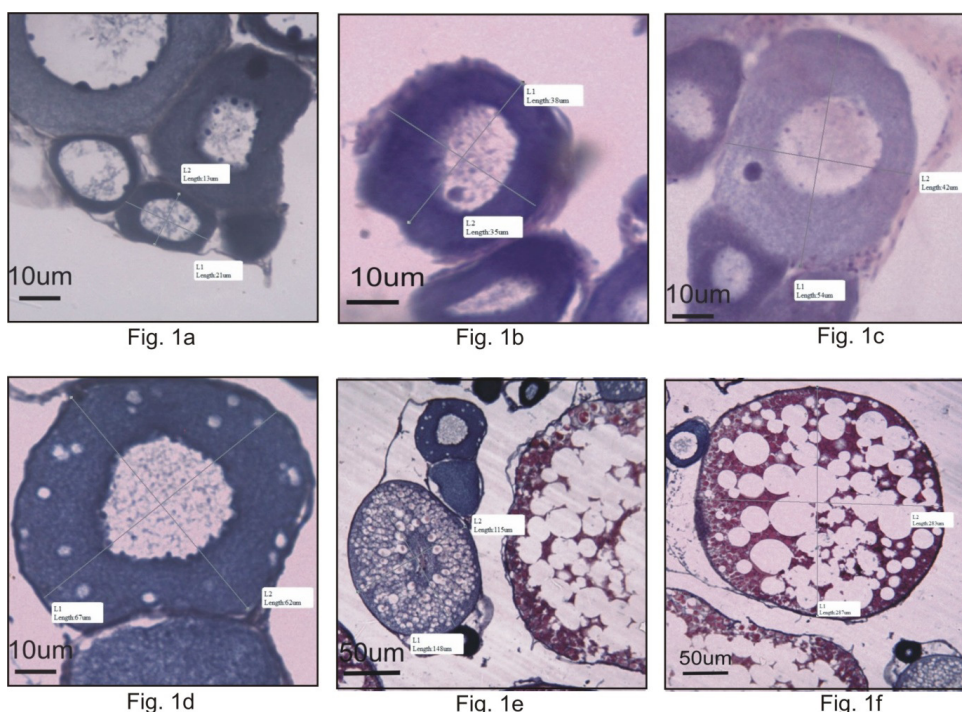


Fig. 1 Various oocyte stages in *C. punctata*.  
 Fig. 1a, Primary oogonia.  
 Fig. 1b, Chromatin nucleolus oocyte.  
 Fig. 1c, Early perinucleolar oocyte.  
 Fig. 1d, Late perinucleolar oocyte.  
 Fig. 1e, Vitellogenic oocyte.  
 Fig. 1f, Ripe oocyte.

**Discussion:**

Recently oocyte stages in teleosts studied in perspective of oogenesis. This approach to study the oocyte stages widely used by many authors (Saeed et al., 2010; Higashino et al., 2000). Five to eight stages of oocyte were reported in teleost fish (Fishelson et al., 1996; Unal et al., 1999; Gokee et al., 2003). Seven stages of oocytes were reported in *Mystus tengara* (Mayor et al., 1988) and in

*Dicentrarchus labrax* (Brandao et al., 2003) respectively. Six oocyte stages were reported in present study.

GSI is correlated with gonadal development (Rae and Calvo, 1995; Zimmerman 1997; Koya et al., 1998). Maximum GSI was reported during spawning phase. Similar reports were describe in *Cynoglossus arel* and *C. lida* (Rajguru, 1992), *Potogonotothen tessellata* (Rae and Calvo, 1995) and in rainbow trout, *Oncorhynchus mykiss* (Sharma and Bhat, 2014).

Cystovarian type of ovary was exhibited by *C. punctata* as central lumen of ovary continue posteriorly with lumen of oviduct. Semi cystovarian type of ovary present in Salmoniformes whose gonad open to the coelomic cavity, with oocytes being expelled by funnels (Narahara, 1981)

Different terminology were ascribe to different stages of oogenesis. In spite of using Roman numerals to describe oocyte stages terminology used in *Oncorhynchus mykiss* was used in present study (Sharma and Bhat, 2014).

Present study confirm the subsequent growth of oocyte from primary oogonia to ripe oocyte. Each stage is significantly larger than previous oocyte stage ( $P < 0.05$ ). Similar results were found in common carp (Shirali et al., 2012), *Oreochromis niloticus* (El – Saba et al., 2013) and in *Oncorhynchus mykiss* (Sharma and Bhat, 2014)

#### Acknowledgement:

The author acknowledges UGC, New Delhi for financial assistance under Rajiv Gandhi National Fellowship (F-1-17.1/2013-14/RGNF-2013-14-ST-MAH-37551(SA-III/Website). The author acknowledges support and facility provided by PGTD of Zoology, RTM Nagpur University, Nagpur.

#### References:

- Belsare DK** (1962). Seasonal changes in the ovary of *Ophiocephalus punctatus*. Indian Quarterly Journal of Fisheries, 9:149-157.
- Brando CAS, Valentin MDM, Caromaschi EP** (2003). Ovary maturation stages and oocyte features in three species of the neotropical fish *Hemiodus spp.* Brazilian Archive of Biology and Technology, 46:3-35.
- Casadevall M, Bonet S, Matallanas J** (1993). Description of different stages in *Ophio donbarbatum* ( Pisces, Ophiidae). Environmental Biology of Fishes, 36: 127-133.
- Chakrabarty NM** (2006). Murrels and murrel culture, Narendra Publishing House. New Delhi.
- El-Saba A, Abd Rabou MI, El- Sakhawy MA, El-Shammaa MA, Hussein SM** (2013). Seasonal changes in the histology of the ovaries of Nile tilapia *Oreochromis niloticus*. Journal of Veterinary Anatomy, 6(2):1-21.
- Fishelson I, Goren M, Van Vuren J, Manelis R.** (1996). Some aspects of the reproductive biology of *Barbus spp., Capoetada ascina* and their hybrids (Cyprinidae, Teleostei) in Israel. Hydrobiologia , 317: 79-88.
- Gokee MA, Cengizier I, Ozak AA** (2003)(Gonad histology and spawning pattern of the white grouper (*Epinephelus aeneus*) from Iskenderun Bay ( Turkey) . Turk Journal of Veterinary and Animal Science, 27: 957-964.
- Hoar WS** (1969).Reproduction. In: W.S. Hoar and D.J. Randall, Fish Physiology. Academic Press, London, 3 : 1-72.
- Koya YT, Itazu T, Inque M** (1998). Annual reproductive cycle based on histological changes in the ovary of the female mosquitofish, *Gambusi aaffinis* in central Japan. Ichthyological Research, 45: 241-248.
- Lillie RD** (1965). Histopathologictechnic and practical histochemistry,3rd edition, McGraw-Hill Book Co., New York.
- Malhotra YR, Jyoti MK and Gupta K** (1978). Ovarian cycle and spawning season of *Ophiocephalus punctatus* , inhabiting Jammu waters, India. Japanese Journal of Ichthyology, 25(3): 1978.
- Mayor I, Shackely SE, Ryland JS**( 1988). Aspects of reproductive biology of *Dicentrachus labrax*. In: A histological study of oocyte development .The Fisheries Society of British Isles. Garland Publishers , London.
- Narahara MY**( 1991). Histofisiologia do ovario de telesosteos. Pp. 39-46. In : MY Narara (eds.) Histologia de peixes. FUNEP ,Jaboticabal, 77p.
- Rae GA and Calvo J** (1995). Annual gonadal cycle and reproduction in *Patagonotothen tessellata* from the beagle channel, Argentina Journal of Applied Ichthyology, 11: 60-70.
- Sharma RK and Bhat RA** (2014).Histoarchitectural variations during oocyte growth in rainbow trout (*Oncorhynchus mykiss*). International Journal of Fisheries and Aquatic Studies, 2(2): 177- 183.
- Shirali S, Erfani MN, Mesbah M. Sefoabab Sjappro MR**( 2012). Histological studies of common carp ovarian development during b reeding season in Khouzestan Province, Iran. World Journal of Fish and Marine Sciences, 4(2): 159-164.
- Shrivastava PN and Rathi SK** (1970). Effect of radiation on reproductive system of Indian catfish *Heteropneustus fossilis* Bloch. I. Annual cycle in development of reproductive tissue of *Mugilcephalus* L. Zoologia, 44: 53-70.
- Swaroop H** (1954). The development of chondrocranium of *Ophiocephalus punctatus* . Sang University Journal, 1:61-79.
- Tyler CR and Sumpter JP**( 1996). Oocyte growth and development in teleosts. Review of Fish Biology and Fisheries , 6 : 287-318.
- Unal G, Cetinkaya O, Elp M** (1999). Histological investigation of gonad development of *Chalcalburnus tarichi*. Turkey Journal of Zoology, 23(1):329-338.
- West G**( 1992). Methods of assessing ovarian development in fishes: a review, Australian Journal of Marine and Fresh Water Research, 41: 199-222.
- Zimmermann M**( 1997). Maturity and fecundity of arrow tooth flounder, *Atheresthesstomias* from the gulf of Alaska. Fish Bulletin, 95., 598-611.