INTERNATIONAL JOURNAL OF RESEARCHES IN BIOSCIENCES, AGRICULTURE AND TECHNOLOGY
© VISHWASHANTI MULTIPURPOSE SOCIETY (Global Peace Multipurpose Society) R. No. MH-659/13(N)
www.vmsindia.org

Histopathology of Labeo rohita fish infected with Trichodinid parasites

JR Somatkar, DS Dabhade [1] and HV Wanjari [2]
Department of Zoology, Late. Pundlikrao Gawali Arts and Science Mahavidyalaya, Shirpur (Jain) Washim
[1,2] P.G. and Research Department of Zoology, R. A. Arts, Shri M. K. Commerce and Shri S.R. Rathi Science College, Washim. 444505
jaya.somatkar@gmail.com

Abstract
The present study was undertaken to study the histopathological effect of Trichodinid ectoparasites on Indian major carps, *Labeo rohita, Catla catla and Cirrhina* mrigala. The results of the present study indicates heavy infection of Trichodinid ectoparasites on gill surface that result in reduction and disruption of the respiratory surface that cause debilitary effect on health of fish.

Key words: Histopathology, Trichodinid parasites, *Labeo rohita*, Freshwater fish

Introduction

Trichodinids are one of the largest and most widely dispersed group of ectoparasites in freshwater environment. Ciliated protozoa (Trichodinids) are among the most common external parasites present on the skin and gills of fish (Dickerson and Clark, 1996; Lom, 1995, Chandra,2006). The ectoparasitic Trichodinids have been earlier reported by many workers in Indian fishes from various regions. Mukherjee and Haldar (1982) were the first in India, who reported the members of the genus *Tripartiella*. After that Samal (1987), Sarkar (1988), Saha *et al.* (1995), Basu and Haldar (1998), Mitra and Haldar (2003), Mohilal and Hemananada (2012), Somatkar and Dabhade (2015) have reported many species of *Tripartiella* from India. But pathological effect of these parasitic species is rare studied area hence the present investigation is carried out to study the pathological effect of of Trichodinid ectoparasites on gill surface of Indian major carps with the help of histopathology tool.

Histopathology is an important disease diagnostic tool that detects early signs of disease not easily recognized on gross examination and helps in etiology and prevention of disease **(Meyers and Hendricks, 1982).** Furthermore, the alterations found in these organs are normally easier to identify than functional ones **(Fanta *et al.*, 2003),** and serve as warning signs of damage to animal health **(Hinton and Laurén, 1990).**

The present study is also aimed in order for public understanding and support to make the people aware of the value of fish by improving protective measures against parasitic diseases with the help of histopathology tool.

Materials and Methods

The host fishes for the present study were collected from various dams and local fish market of Washim from 2010 to 2014. The collected fishes were brought to laboratory for necropsy procedure for examination of Trichodinid ectoparasites. Trichodinid ectoparasites present on fish gills were studied by using smear method. Air-dried smears with trichodinid ciliates were impregnated with Klein's dry sliver impregnation technique (Klien, 1958) and identified using standered literature.

For histopathological analysis, the infected gill tissues were fixed in 10 % buffered formalin for 24 hour, embedded in paraffin, cut into 4 µm thick sections and stained with hematoxylin and eosin. The photographs of the histopathology slides were taken with the digital camera of microscope. Identification of Trichodinid parasites in tissue sections was done by using standard literature [16-17]

Result and Discussion

The present study reported four species of Trichodinid ectoparasites, *Trichodinella epizootica, Tripartiella obtusa, Tripartiella copiosa, Tripartiella bulbosa* with strongest effect noticed on target organ i.e. on gill surface.

The infected fishes were very slimy and the gills appear pale in colour with excessive mucous production. The phase contrast microscopic examination of the gills of carp revealed moderately altered structure when invaded by Trichodinids. (Fig.1-4). Trichodinids were located between secondary lamellae, on the tip of the (sometimes shortened) secondary lamellae. It was observed that the parasite induced intensive proliferative changes on the epithelium of the gill filaments and the proliferation appeared extending along the whole gill filaments. As a result, the secondary lamellae fused together and appeared as one unit and in many cases, the proliferated epithelial cells displayed degeneration and desquamation in most of the superficial cells in of different degree either vacuolar and/or complete (Figure 5 and 8).

Although most gills examined were functionally normal, certain changes of gill structure were regularly noticed, e.g. subepithelial oedema of the secondary epithelium, focal hyperplasia between secondary lamellae, curling of pillar cell system and mild circulatory changes, together with hypertrophy and hyperplasia of chloride and mucous cells. In

addition to these lesions, an excessive accumulation of mucus on gills was also seen on gills of infested fishes with *Trichodinid infection* caused serious pathological lesions in gills, such as hyperplasia of the epithelial cells, clubbing and fusion of the gill filaments, which have been previously reported by many authors **(Padnos and Nigrelli, 1942). Davis (1947)** reported hyperplasia and necrosis in gill tissue of fishes infected by Trichodinid ciliophorans. **Sarig(1971)** observed ***Trichodina*** sp., ***Tripartialla*** sp. and ***Glassatella*** sp. to be so abundant on gills and skin that they destroy the normal structure of epithelium of host fishes. **Lom (1973)** extensively studied the mechanism of the injury of host cells by Trichodinid ciliophorans. Extensive damage to gills i.e. hypertrophy, vacuolar degeneration and desquamation of epithelial cells are due to the presence of trichodinids was also reported by **Ahmed (1976), Mcardle (1984), Eisa *et al.*(1985), Das and Pal (1987) and Hassan (1999), Acharya and Dutta (2005), Vera *et al.* (2003)**

It was observed that the Trichodinid ciliophorans are pathogenic to host fishes if present in large numbers **(Lom, 1973).** The histopathological observations indicate that the infestation with Trichodinid ciliophorans result in a wide range of deleterious changes ranging from hypertrophy and hyperplasia of gill epithelium. The histological damages in the gills inhibit the normal physiological functions of the gills**. Hughes (1972)** observed that proliferation and swelling of gill epithelium significantly reduced the oxygen uptake capacity of gills. Heavy mucous production by fish gills as observed implicates hypoxic condition **(Gardener, 1975). Lom (1973)** reported the presence of stimulating substance of fish which helped Trichodinids to proliferate massively. The presence of high amount of mucous might have provided a congenital environment for ciliates. The massive mucus production on infested fishes is a defense mechanism produced by the host to eliminate the parasite. It is likely that those moderate gill alterations were not induced exclusively by trichodinids, since they coincided with unfavorable environmental conditions in the fish-ponds, i.e., low dissolved oxygen concentration, high water temperature, high stock density, etc., which could also lead to increased mortality of fish fry in the rearing ponds **(Bykovskaya- Pavlovskaya, 1964; Kabata, 1985).**

Photoplate I: A-D: Silver impregnated adhesive disc of A- Tripartiella obtusa ,B-:*Tripartiella copiosa* ,C-*Tripartiella bulbosa* , D- *Trichodinella epizootica (Oil immersion photography)* . :E-F:Examples of appearance of stained Trichodinid parasites in heavy population on Gill surface of *Labeo rohita*.

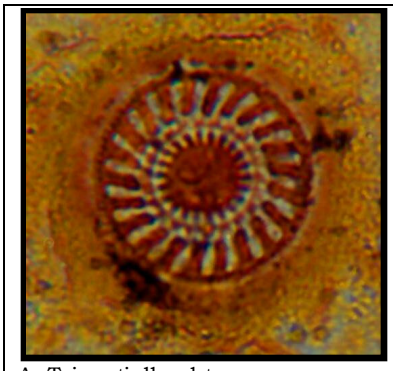

A: Tripartiella obtusa

B:Tripartiella copiosa

C: Tripartiella bulbosa

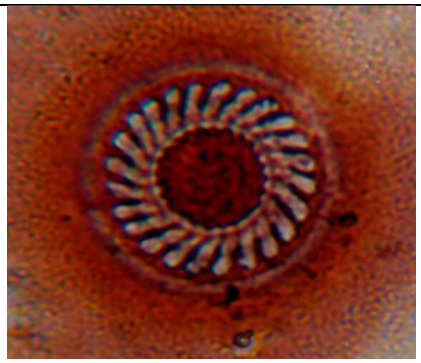

D: Trichodinella epizootica

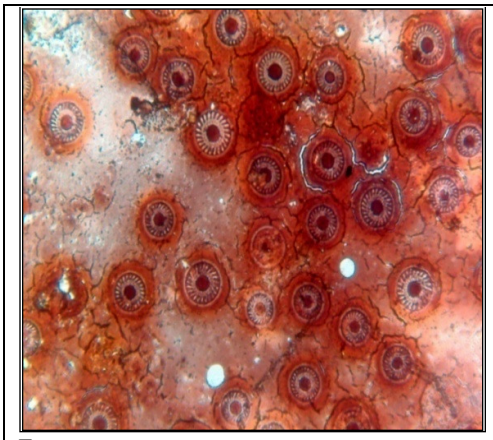

E

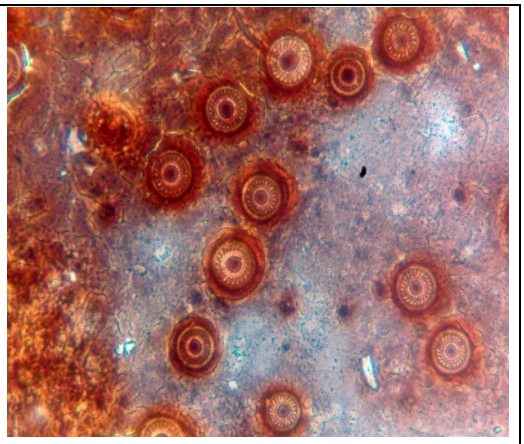

F

Photoplate II: Histopathological effect of Trichodinid ectoparasites on gill tissues of freshwater fish, *Labeo rohita. A: Healthy gills of Labeo rohita,10X; B-Infected gills of Catla Catla(40X); C: Infected gills of Labeo rohita,20X; D:Infected gills of Cirrhina mrigala,20X; E-F: Infected gills of Labeo r*ohita,20X.(Eosin and Haematoxylin staining)



A

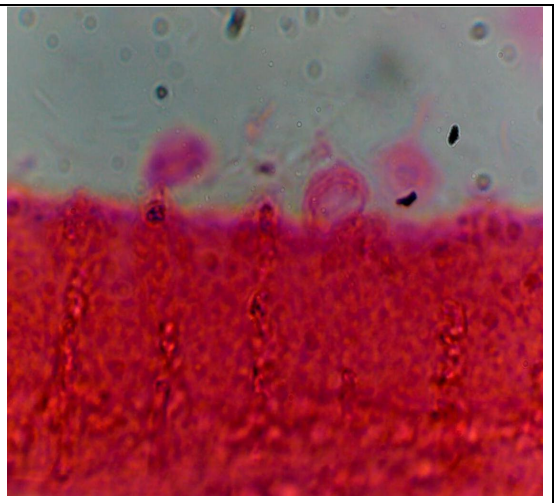

B

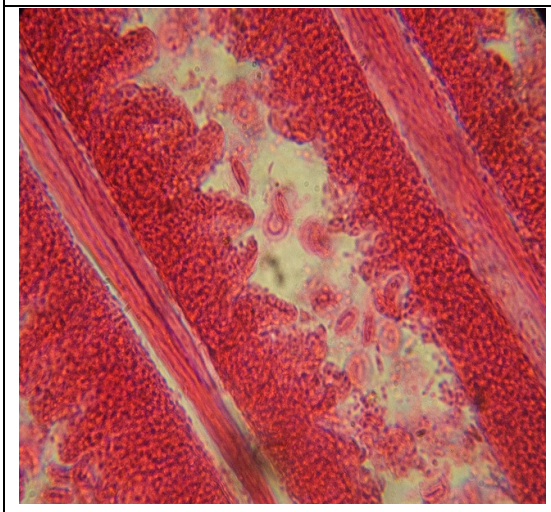

C

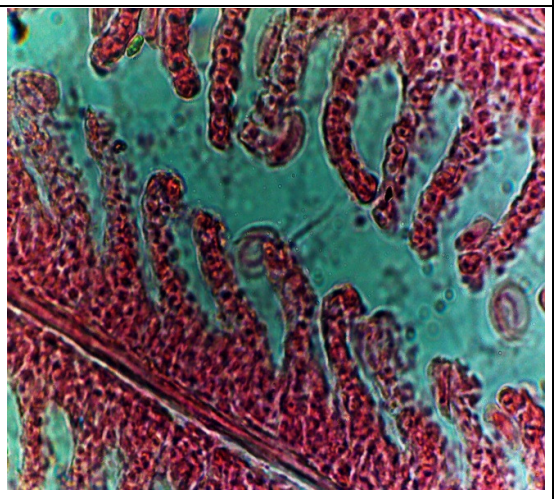

D

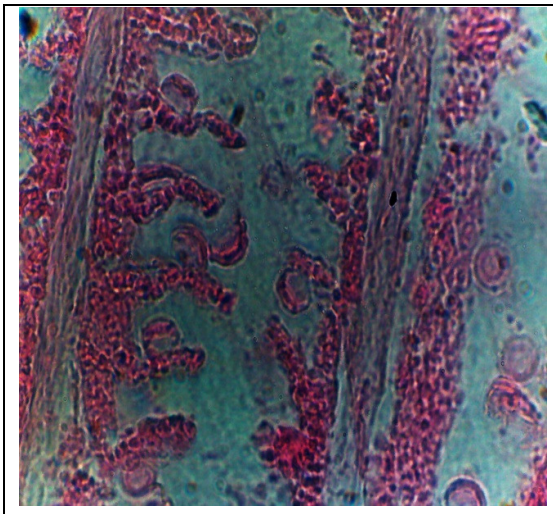

E

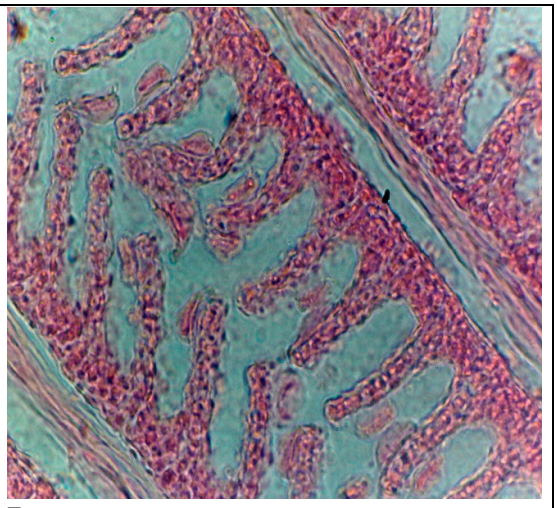

F

Conclusion

Histopathological analysis of *Labeo rohita* revealed four species of Trichodinids namely *Trichodinella epizootica, Tripartiella obtusa, Tripartiella copiosa, Tripartiella bulbosa* seriously damage the epithelial or epidermal cells by their constant ectoparasitic attachment and movement. Under these circumstances the trichodinids behave like serious ectoparasites, feeding on disruptive surface and associated bacterial growth. These may even penetrate into gills or skin tissues and feed on it and multiply in large numbers. The damage of gills due to presence of this parasite might be the cause for mortality of carps often encountered. So in order to prevent the tissue damage of fish due to Trichodinid ectoparasites, it is needed to disrupt the steps of parasitic transfer from one host to another, from one water body to another with suitable and effective preventive and control measures

Bibliography

Acharya S. and T. Dutta (2005): Tissue level reactions in Catla catla(Hamilton-Buchnan) due to trichodinid ciliophoran, Tripartiella sp. Infections. Indian J. Fish., 52(2): 159-163.

Ahmed A.T. (1976): Trichodiniasis of gold fish and other carps. *Bangladesh J. Zool.*, 4: 12-20.

Basu S. and Haldar D.P. (1998). Comparative study on prevalence of protozoan parasite in pure and hybrid carps. Environ Ecol 16(3):584–587

Bykovskaya-Pavlovskaya IE, 1964) Key to parasites of freshwater fish of USSR. Israel Program for Scientific Translations, Jerusalem. Bowser PR, Conroy JD (1985). Histopathology of gill lesions in channel catfish associated with *Henneguya. J. Wildlife Dis. Vol.*21(2):177–179,

Klien B.M. (1958). The dry silver method and its proper use. J Protozool 5:99–103.

Das M.K. and R.N. Pal (1987): Histopathology of gill infestation by monogenea and urceolariid ciliates in carps cultured in India**.** *Indian. J. Prasitol.,vol. 11(2): 127-130*

Davis H. S. (1947): Studies of the protozoan parasites of freshwater fish. *Fish. Bull. Fish. Wildl. Serv. US.* 41, 1-29.

Dickerson H.W. and Clark T.G. (1996). Immune response of **fi**shes to ciliates. Annual Review of Fish Diseases 6:107-120.

Eisa M.E., El-Shazly H. O., Rizk M. H. (1985): A contribution to the pathological changes of ectoparasitic trichodinids affected salt water fish (gray mullet fingerlings) in Raswa fish farms. *J. Egypt. Vet. Med.,vol.45*: 107-113.

Fanta E., F. S. Rios, S. Romao, A. C. C. Vianna and S. Freiberger. (2003): Histopathology of the fish *Corydoras paleatus* contaminated with sublethal levels of organophosphorus in water and food. *Ecotoxicology and Environmental Safety*: 119-13

Gardener G. R. (1975): Chemically induced lesions in estuarine or marine teleosts. In:The pathology of fishes, W.E.Ribelin and G. Migaki(Eds.), *University of Wisconsin Press, Madison.*

Hassan Mohamed Abd El-Azez Hassan (1999): Trichodiniasis in farmed freshwater *Tilapia* in Eastern Saudi Arabia. *J. Kau: Mar. Sci, Vol.*10:157-168.

Hinton, D. E. and D. J. Lauren. (1990): Liver structural alterations accompanying chronic toxicity in fishes: potentioal biomarkers of exposure. Pp. 51-65. In: McCarthy, J.F. & L.R. Shugart (Eds.). Biomarkers of Environmental Contamination. Boca Raton, Lewis Publishers.

Hughes G..M. (1972): Morphometrics of fish gill. *Resp. Physiology vol.*14: 1-26.

Kabata Z. (1985): Parasites and diseases of the fish cultured in the tropics. *Taylor & Francis, London and Philadephia.*

Lom J.(1973): The adhesive disc of Trichodinella epizootica: ultrastructure and injury to the host tissue. *Folia parasitol.,vol.20*: 293-302.

Lom J. and Dykova I. (1992). Protozoan parasites of fishes. Developments in Aquaculture and Fisheries Science, vol. 26: 315.

Lom J. (1995). Trichodinidae and other Ciliates (Phylum Ciliophora). Fish Diseases and Disorders: Protozoan and Metazoan Infections. CAB International, Cambridge 229-262.

Meyers T.R. and J. D. Hendricks (1982): A summary of tissue lesions in aquatic animals induced by controlled exposures to environmental contaminants, chemotherapeutic agents and potential carcinogens. Marine Fisheries Review, 44(12):1-17

Mitra A.K. and Haldar D.P. (2003). Record of a trichodinid ciliophoran, *Tripatriella copiosa* Lom, (Mobilina: Trichodinidae) infesting gills of *Mystus vittatus* (Bloch) from Canning, South 24 Paraganas. Environ Ecol 21:759–763.

Mukherjee M. and Haldar D.P. (1982). Observations on the urceolariid ciliates of the genera *Trichodina* and *Tripartiella* in freshwater teleosts. Arch Protistenkd 126:419–426.

Mohilal N. and Hemananda T. (2012). Record of the species of *Tripartiella* (Lom, 1959) from fi shes of Manipur. J Parasit Dis (Jan-June 2012) 36(1):87–93.

Padnos M. and R. F. Nigrelli (1942): Trichodina spheroidesi and Trichodina hatti spp. nov. parasitic on the gills and skin of malne fiin, with special reference to the life history of Spheroidesi. *Acta Zool.vol.27, 65-72.*

Samal K.K. (1987). Observations on the protozoan parasites in the brackish and freshwater edible fi shes of Orissa. Ph. D. Thesis, Kalyani University.

Saha B.S., Bandhyopadhyay P.K. and Haldar D.P. (1995). Biodiversity of trichodinid ciliates in fresh water fi shes of West Bengal. Environ Ecol 13(4):814–823.

Sarig S. (1971): Diseases of Fish. The prevention and treatment of diseases of warm water fish under subtropical conditions with special emphasis on intensive fish farming. *Eds. Sniezko S. F. and H. R. Axelrod. T. F. H. publications Hong Kong.*

Sarkar S. (1988). Studies in the Urceolariid ciliates (Peritricha,Mobilina) from edible fi shes of West Bengal. PhD Thesis, Kalyani University, West Bengal, 250.

Somatkar J.R. and Dabhade D.S. (2015): Trichodinid ectoparasites from fresh water fishes of Washim region of Maharashtra, India Biosci. Biotech. Res. Comm. 8(1): 35-42.

Vera N., Simonovic P and P.Vesna(2003): Preference of Trichodinids (*Ciliata, Peritrichia*) occurring on fish-pond carp for particular organs and some morphological implications. *Acta Veterinaria (Beograd),* Vol. 53. No. 1: 41-46.